



## Minimally Invasive Management of Crown Fracture by Fragment Reattachment with Fiber Post- A case report

Dr. Ankita Gote<sup>1</sup>, Dr. Ambar Raut<sup>2</sup>, Dr. Diksha Naik<sup>1</sup>, Dr. Radha Deshmukh<sup>1</sup>, Dr. Avishkar Patil<sup>1</sup>, Dr. Pallavi Pawar<sup>1</sup>.

1. MDS student, Department of Conservative Dentistry and Endodontics, Swargiya Dadasaheb Kalmegh Dental College and Hospital, Nagpur

2. Professor, Department of Conservative Dentistry and Endodontics, Swargiya Dadasaheb Kalmegh Dental College and Hospital, Nagpur

(Received: 3 November 2025

Revised: 17 February 2026

Accepted: 18 April 2026)

### KEYWORDS

Direct composite

Stamp technique

Natural Occlusal Anatomy

**ABSTRACT:** Even a small occlusal disparity following direct restorations causes discomfort for the patients because the stomatognathic system's proprioceptors respond appropriately to pressure. Patients eventually adjust to their new habitual occlusal position in order to compensate, which results in severe long-term craniomandibular disorders. In order to accurately and quickly replicate the occlusal topography for a direct composite resin repair, a stamp technique is suggested.

Introduction: Restoring the shape, function, and occlusion of each tooth that the disease has destroyed is one of the primary goals of a restoration. In contrast to indirect restorations, direct restorations provide difficulties in getting the same intra-orally, whereas contact, contour, and occlusion are well controlled and obtained in the laboratory. It may not produce an exact replication of the form and occlusion and can be time-consuming and technique-sensitive. The many matrices that are available for metallic and non-metallic restorations primarily make it possible to obtain the proximal surfaces' shape and contact [1], but they do not aid in establishing exact occlusion. Because the occlusal carving is left up to the free hand's talent and dexterity, there is a chance that it will be overdone or underdone, leading to overdone or underdone repaired surfaces. Occlusal inconsistencies resulting from this can be slight or substantial. Furthermore, the surface finish produced by using abrasives would not be as smooth as that produced by using a matrix.

Trauma-related occlusion is an iatrogenic lesion that, if ignored during surgery, would change the stability of the entire stomatognathic system. [2]

While preserving a good and stable inter-cuspal relationship of centric occlusion with no indications of tooth wear or mandibular dysfunction, a functional occlusion encourages beneficial adaptation of the neuromusculature, temporomandibular joint, teeth, and its supporting structures. [3,5] Occlusion is crucial because orofacial integrity is essential to psychological well-being. [4]

One method for direct composite resin restorations that Dr. Waseem Riaz, a practitioner in London, suggests is the "Stamp technique," which makes it simple to obtain the exact occlusal topography. Additionally, it has been documented for the rebuilding of worn-out dentitions using vertical bites [9].

Similar to an index, a stamp is a little putty impression created prior to dental preparation for a



complete crown. By replicating the initial, unprepared tooth structure, this stamp reproduces the original anatomy of the tooth structure.[6, 7, 8] When the occlusal surface is nearly undamaged prior to the restorative surgery, this approach is employed.[7] Wax is used to block cavitations in mild or moderately cavitated carious lesions, and the occlusal pattern is sculpted on the wax.

Case: Figures (a) through (m) show the detailed process.

A rubber barrier was used to isolate the cavitated tooth that needed to be repaired. Base plate wax prevented cavitated caries in the mesial to oblique ridge. Using an applicator tip, a single coat of petroleum jelly/vaseline, which serves as a separating agent, was applied to the occlusal surface. For convenience, the scissors were used to cut the tip of a microbrush. The occlusal surface was covered with flowable composite material, and the microbrush was then gently digitally compressed across it. An occlusal stamp was created after it was light cured.


Pumice prophylaxis was carried out with pumice slurry using a rubber cup in a contra angle micromotor handpiece at a moderate speed to eliminate the debris and the separating agent. Tungsten carbide bur was used to prepare the cavity and dig the caries using an Airtor handpiece. Using a disposable needle and syringe, selective enamel etching was carried out using 37% orthophosphoric acid [Tetric N Etch Ivoclar vivadent] and rinsed with water.

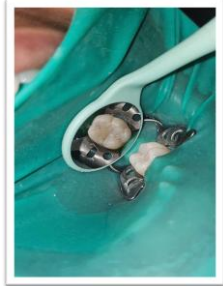While the dentin was blot dried, the cavity was dried using a chip blower to give the enamel a crisp white appearance.

Packable resin composite resin [B2 shade Tetric N ceram, Ivoclar vivadent] was gradually added after the bonding agent [Tetric N Bond, Ivoclar vivadent] was placed with an applicator tip and cured for 20

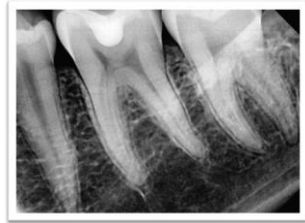seconds. LEDs (Unicorn Denmart) were used to light-cure the restoration for 20 seconds.

A cling film was placed to the surface following the addition of the last increment. The cling film was covered with the manufactured microbrush stamp. After the cling film was removed, a sharp hand tool was used to remove the excess. After that, the resin composite was hardened. A single-step Pogo composite polishing kit was used for polishing.





(l)



(m)

### Discussion and Conclusion:

#### Advantages

- A quicker process because it takes less time to manually recreate occlusal anatomy
- Less material is used.
- Less time is spent shifting the chair side [saving articulating paper and time]

Reduced chair side time throughout the polishing and finishing process

- Since it is a copy, it replicates the original occlusal anatomy.
- No extra equipment is required. [XTS anti-stick devices]

#### Drawbacks

- In cases of frequent restoration failure, the index has lower clinical efficacy.
- Because it is impossible to replicate severe holes and cracks in the occlusal stamp, the index cannot replicate these flaws.
- There is a chance that the stick will slip off the stamp, which could cause aspiration or choking.
- Economical because the supplies needed for this method, like the microbrush, and
- The cost of flowable composites is high.

The following additional affordable materials could be taken into consideration: Sealants for pits and fissures

- Poly methyl methacrylate [transparent]
- Resin with patterns • Material for gingival dams
- The template was vacuum-formed.
- Material for bite registration

For teeth with nearly complete occlusal anatomy, the microbrush stamp technique is a simple and practical way to replicate precise occlusal topography.

#### References:

1. 2. 3. 4. 5. 6. 7. 8. 9. Geena MG, Kevin RG. Building Proximal Contacts and Contours in Resin Composite Restorations: A Technical Report. *Journal of Scientific Dentistry* 2014;4(1):62-9.
2. Dawson EP. Evaluation, Diagnosis and treatment of Occlusal problems, 2 nd Ed., C.V. Mosby Co.(Toronto): 1989.
3. Gross MD, Mathews JD. Occlusion in Restorative Dentistry, Technique and Theory, 1 st Ed. Churchill Livingstone (NY): Longman Group limited; 1982.
4. Klienburg I, Jagger R .Occlusion and Clinical Practice : An Evidence Based Approach 1 st Ed. Wright publications (UK): Elsevier limited ;2004.
5. Roberson TM, Heymann IV, Swift HV, Edward J.VI, Sturdevant ,Clifford M. Sturdevant's Art and Science of Operative Dentistry, 5 th Ed. Mosby publications(PA):Elsevier limited; 2006
6. Kilian Molina , Direct Posteriors- Cases-Shadeguides, Stamp technique Part-1: <http://www.styleitaliano.org/stamptechnique-part-1>



- 
7. Abdelrahman Tawfik Direct Posteriors - Community Stamp Technique, community <http://www.styleitaliano.org/stamp-technique>
  8. Varsha R K, Microbrush Stamp Technique – Case report, General Practice Feature, 98 September 2015 // [dentaltown.com](http://dentaltown.com), 98-9.
  9. Simon T. Ramseyer, Christoph Helbling, Adrian Lussi. Vertical Bite Reconstructions of Erosively Worn Dentitions and the “Stamp Technique” - A Case Series with a Mean Observation Time of 40 Months. The Journal of Adhesive Dentistry 2015; 17(3):68-99