



A Systematic Review of Aesthetic Outcomes in Implant Prostheses Using Pink and White Esthetic Scores.

G. Nivedhita¹, Dr. V. Sreedevi²

¹Post Graduate Student, Department of Prosthodontics, Sree Balaji Dental College and Hospitals, Velachery Rd, Narayanapuram, Pallikaranai, Chennai, Tamil Nadu 600100.

² Professor and PhD Scholar, Department of Prosthodontics, Sree Balaji Dental College and Hospitals, Velachery Rd, Narayanapuram, Pallikaranai, Chennai, Tamil Nadu 600100.

(Received: 16 February 2026

Revised: 25 March 2026

Accepted: 10 April 2026)

KEYWORDS

Aesthetic outcomes, implant-supported prostheses, Pink Esthetic Score (PES), White Esthetic Score (WES), implant placement.

ABSTRACT:

Objectives: With the increased expectation for natural, aesthetically pleasing restorations from patients, optimal aesthetic outcomes in implant dentistry have gained growing importance. This systematic review sought to summarize the existing evidence from randomized controlled trials evaluating aesthetic outcomes in the anterior maxilla with regard to the Pink Esthetic Score (PES) and the White Esthetic Score (WES).

Materials and Methods: Randomized controlled trials about anterior maxillary implants with PES and WES have been included. The indices uniformly appraise the peri-implant tissues and prosthetic elements, providing a sound rationale for aesthetic evaluation. Digital workflows, immediate placement of implants, types of restorations, and material selection were analyzed for impacts on aesthetic and functional outcomes.

Results: The studies showed that digital workflows improved the accuracy of implant placement, and thus the scores for PES/WES were higher. Immediate implant placement resulted in early aesthetic benefits but raised concerns regarding the stability of the peri-implant tissue. Screw-retained restorations showed fewer biological complications than cemented restorations. Lithium disilicate and zirconia crowns showed better aesthetics. Short implants performed as well as standard implants in functional and aesthetic outcomes, avoiding the morbidity associated with sinus augmentation.

Conclusion: Achieving the best aesthetic results in implant-supported prostheses requires advanced materials, digital technologies, and minimally invasive techniques for predictable long-term results. PES and WES facilitate comprehensive evaluations of aesthetic and functional challenges. Future research should emphasize long-term studies, diverse populations, and patient-reported outcomes to refine these indices and improve implant dentistry practices.

1. Introduction

A search for optimal aesthetic outcomes has gained ever-increasing relevance in the field of implant dentistry since patients' requirements for naturally appearing, aesthetic restorations are mounting. A range of implant-supported restorations now offers reliable and functional replacement options for missing teeth. With implant-supported restorations providing solutions for almost any condition, aesthetic outcomes are equally dependent on soft and hard tissue integration for the overall success of prosthesis. This calls for an extensive and standardized assessment of the peri-implant soft tissue and the prosthetic elements. Two of the widely accepted instruments used in measuring the aesthetic outcomes of

implant-supported restorations are the Pink Esthetic Score (PES) and White Esthetic Score (WES) [1].

These indices provide a systematic approach to the assessment of critical aspects of implant aesthetics. The PES focuses on the peri-implant soft tissue, measuring parameters such as tissue contour, color, texture, and the alignment of the gingival margins. The WES measures the restoration itself, considering crown form, shade, translucency, and surface texture. Together, these indices provide a structured approach to objectively assessing the overall aesthetic success of implant-supported restorations [2]. The applications of PES and WES in clinical and research fields have gained popularity as the tools can standardize the aesthetic assessments. The



devices are invaluable for clinicians and researchers who need to measure outcomes of treatment, develop further surgical and prosthetic techniques and improve patient satisfaction. Questions related to their consistency and to what extent they can be used as predictors of long-term treatment outcomes have been left as a concern. Moreover, the intricate interaction between biological, mechanical, and aesthetic factors emphasizes the necessity of a holistic approach in implant dentistry [3].

The soft tissue around the implant, affected by surgical techniques, implant placement, and prosthetic design, is an important determinant of the aesthetic integration of the restoration.

Similarly, the design of the restoration, material properties, and shade matching are essential for achieving visual harmony with the adjacent teeth. This would provide a better evaluation of treatment success, taking into account these factors through the PES and WES [4]. The aim of this systematic review is to compile and review the existing literature concerning the application of the Pink Esthetic Score and White Esthetic Score in the assessment of implant-supported restorations and prostheses. By focusing on studies that utilize these indices in diverse clinical contexts, this review seeks to elucidate their role in guiding treatment planning, addressing aesthetic challenges, and improving patient outcomes. Specifically, the review will explore how PES and WES have been used to evaluate implant aesthetics, their limitations, and their potential to inform clinical decision-making.

Ultimately, the work aims to provide a comprehensive overview regarding the current evidence base based on the strengths and limitations that exist in PES/WES as aesthetic evaluation tools. In doing so, this review hopes to bridge the gaps evident in the literature, thereby aiming to support the development of the evidence-based approach to arriving at superior aesthetic outcomes through implant dentistry. This effort will not only benefit the clinicians and researchers but it will also contribute to improved care and satisfaction of the patient in the field of restorative dentistry.

2. Methods

This systematic review aimed to identify, assess, and synthesize randomized controlled trials and case-control studies comparing advanced surgical techniques or

different prosthetic materials with conventional prostheses. Studies without clear interventions, comparators, or lacking conventional prostheses as a control were excluded. Only studies focusing on implant-supported prostheses in the anterior region or involving a single implant were included, with primary outcomes being the Pink Esthetic Score (PES) or White Esthetic Score (WES) and secondary outcomes including patient satisfaction, soft tissue health, and complication rates. Studies set in clinical or dental practice settings were eligible, while those in experimental or animal contexts were excluded. Searches were conducted in multiple databases, including PubMed, MEDLINE via Ovid, MEDLINE via Ebsco, The Cochrane Library for Cochrane Reviews, CENTRAL, and Embase, from inception to January 10th, 2024. We also manually reviewed reference lists, performed citation analyses, and utilized "similar articles" features in the databases. The search was restricted to studies published in English, excluding conference abstracts, editorials, and reviews. Two authors independently screened titles and abstracts, reviewed full texts, and resolved discrepancies by consensus. Data extraction involved recording study characteristics and outcomes using a standardized form piloted on three studies. Data extraction was done using a piloted form, and risk of bias was assessed using the Cochrane Risk of Bias 2 tool. Meta-analyses were planned using appropriate models if enough studies with comparable outcomes were available. Missing data were not pursued, and publication bias was not assessed due to the limited number of included studies. Search strategies and details are provided in the appendices. This systematic review was conducted in accordance with the PRISMA (Preferred Reporting Items for Systematic Reviews and Meta-Analyses) guidelines. Ethical approval was not required for this study as it is a systematic review of previously published data.

3. Results

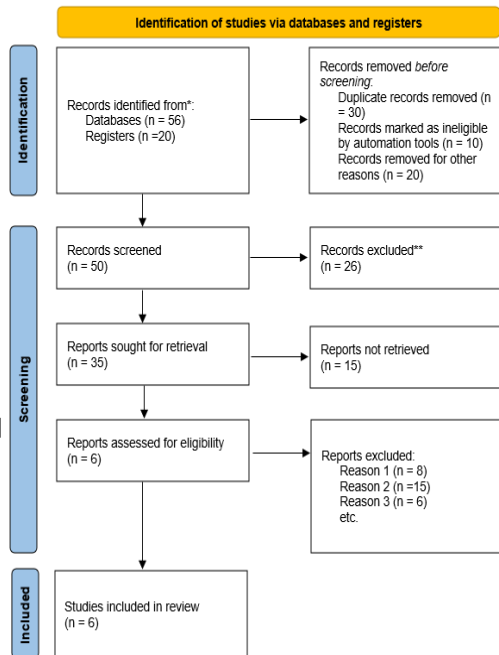


Figure 1: PRISMA Flow Diagram

Table 1: PICO table of articles selected.

Study	Population	Intervention	Comparison	Outcome
Study 1	Participants with a failing tooth in the maxillary aesthetic zone.	Immediate implant placement with immediate provisionalization (IP) after primary wound closure with a free gingival graft.	Immediate implant placement with delayed provisionalization (DP) after primary wound closure with a free gingival graft.	Change in marginal bone level (primary outcome), along with implant survival, restoration survival and success, peri-implant tissue health, aesthetic indices, buccal bone thickness, and patient satisfaction

Study 2	Sixty patients scheduled for dental implant treatment in the anterior maxillary region.	Implant surgery using a fully guided digital template.	Implant surgery using a partially guided digital template or routine implant-supported restoration treatment (control group).	(secondary outcomes). Accuracy of implant placement (angular, coronal, apical, and depth deviations) and esthetic outcomes (PES and WES values at baseline, 6 months, 1 year).
Study 3	Thirty-two patients receiving implant-supported single-tooth restorations with customized zirconia abutments in the anterior areas.	Screw-retained crowns supported by full-crown abutments (FCA).	Cemented crowns supported by zirconia crowns (ZrC).	Clinical outcomes over 10 years, including prosthetic/biologic complications, marginal bone level (MBL), mucosal recession, and esthetic outcomes (PES and WES).
Study 4	Forty-five patients requiring the extraction and immediate	Lithium disilicate (T1) implant-supported single crowns.	Metal-porcelain (C) and porcelain-layered zirconium (T2) implant-	Aesthetic outcomes: Pink (PES) and White (WES) esthetic scores, patient



	te implanta tion of a single tooth in the anterior maxilla.		supported single crowns.	satisfaction (VAS), radiographic bone levels, and periodontal parameters.
Stu dy 5	Forty patients requiring single- crown restorati ons in the posterior maxilla.	Single- crown restoration supported by short implants (SI) (6 mm).	Single- crown restoration supported by standard- length implants (SLI) (13 mm) in conjunction with maxillary sinus floor augmentatio n (MSFA).	Professional outcomes (PES and WES scores) and patient- reported outcome measures (PROM) including OHIP-14 scores and VAS for peri-implant soft tissue, implant crown, implant function, and overall treatment outcome.
Stu dy 6	Twenty patients requiring single- implant crowns, randomi zed into two groups.	All-ceramic screw- retained single- implant crowns.	Porcelain- fused-to- ceramic (PFM) screw- retained single- implant crowns.	PES, WES, papilla height, peri- implant mucosal margin recession, implant crown volume, outline, translucency, and

				characterizati on.
Stu dy 7	Single tooth implant supporte d prosthesis	Titanium abutment with metal- ceramic crown	Zirconia abutment with ceramic crown	TAG showed Higher mean values than ZAG
Stu dy 8	Endosse ous implants inserted in sites 13 to 23	A provisional phase with soft tissue conditioning using dynamic compression technique	Without a provisional phase	Fixed implant- supported provisional crown showed statistically significant higher modPES scores
Stu dy 9	Patients with a missing maxillar y tooth(15 -25)	Immediate loading	Delayed loading	PES was significantly higher both immediate loading and Delayed loading
Stu dy 10	40 patients with 109 adjacent implants	Adjacent Zirconia Implants	Adjacent Titanium Implants	Esthetic outcomes measured by papillary fill (Jemt score), papilla deficit (mm), soft tissue recession, and implant shadow visibility.



Study 11	30 participants receiving single implant restorations in the maxillary esthetic region.	Monolithic high-translucency multilayer zirconia crowns (Group 1).	Traditional veneered zirconia crowns (Group 2).	Comparison of esthetic outcomes measured through the Visual Analog Scale (VAS) for patient satisfaction and the White Esthetic Score (WES) for professional assessment.
Study 12	40 patients requiring anterior maxillary all-ceramic implant crowns in sites 14 to 24 (FDI).	Prefabricated zirconia abutments with pressed ceramic crowns using the cut-back technique (Group A).	CAD/CAM zirconia abutments with hand buildup ceramic crowns (Group B).	Comparison of esthetic outcomes (Pink Esthetic Score [PES] and White Esthetic Score [WES]), survival rate, peri-implant soft tissue health, and crestal bone stability at baseline, 6 months, and 1 year.

Study 13	Patients receiving immediate implant placement with immediate load post-extractive implants in the aesthetic zone.	Immediate implant placement with subepithelial connective tissue graft using the tunnel technique in the labial area (test group), in addition to deproteinized bovine bone mineral.	Immediate implant placement without a soft tissue graft and without raising a flap (control group), also with deproteinized bovine bone mineral.	Aesthetic outcomes (measured by Pink Esthetic Score [PES]), soft tissue volume changes (thickness and height), implant stability, and peri-implant soft tissue health over a 2-year follow-up period.
----------	--	--	--	---




Figure 2: Risk of Bias assessed for the articles selected.

4. Discussion

The field of implant dentistry, especially in the anterior maxillary region, has dramatically improved with a focus on optimizing aesthetic, functional, and patient-centered outcomes. The included studies provide critical insights into the comparative effectiveness of various treatment



modalities, materials, and surgical protocols, offering evidence-based guidance for clinical decision-making.

Immediate Implant Placement and Provisionalization

In a study Donker et al directly compared immediate placement with immediate provisionalization (IP) to delayed provisionalization (DP) through outcomes such as marginal bone level changes, peri-implant tissue health, and aesthetic indices. Immediate provisionalization has the benefit of early restoration which promotes soft tissue adaptation, and aesthetic results. However, DP was associated with slightly more stable peri-implant tissue stability; thus, perhaps there is a trade-off between immediate aesthetics and longer-term tissue health. This is what aligns with the clinical dilemma of achieving immediate patient satisfaction versus biological predictability in the maxillary aesthetic zone [5].

Accuracy in Placement of Implants with Digital Technology

Lou, Fangzhi et al. compared fully guided digital templates with partially guided and conventional techniques. Fully guided templates had better accuracy by showing reduced angular, coronal, apical, and depth deviations. Such a focus provided higher aesthetic results, as manifest in better PES and WES ratings at one year. Use of digital workflows in implant therapy boosts the predictability of results, specifically in anatomically and aesthetically sensitive areas such as anterior maxilla, thereby making such technical knowledge invaluable in current implant practices[6].

Screw-Retained vs. Cemented Restorations

The debate for screw-retained versus cemented restorations continues to be central within implant-supported prosthodontics. Amorfini, Leonardo et al. compared these approaches in a follow-up of 10 years. Those with FCA screw-retained crowns had diminished biologic complications, notably peri-implantitis, because of the likely elimination of residual cement. Both groups had comparable PES and WES with time. Screw-retained design benefits retrievability and more favorable peri-implant health, leading to better use in complex cases or cases with high biologic risks [7].

Material Selection for Implant-Supported Crowns

Zamora, Guillermo Pardo et al. studied the aesthetic and functional results of lithium disilicate, metal-porcelain, and porcelain-layered zirconium crowns in the anterior maxilla. Lithium disilicate crowns had the highest WES scores because of their superior translucency and biomimetic properties. Porcelain-layered zirconium crowns showed better PES scores due to better integration with peri-implant tissues. The study shows that material selection is important for achieving case-specific outcomes, where aesthetic and mechanical requirements need to be balanced [8].

Short implants versus standard-length implants with sinus augmentation

The study evaluates the use of short implants as an alternative minimally invasive approach to conventional-length implants that require maxillary sinus floor augmentation (MSFA) in a study by Nielsen, Helle Baungaard et al. Short implants presented equivalent aesthetic and functional results but avoided the morbidity of the sinus lift procedure. The patient-reported outcomes (PROMs) through OHIP-14 scores showed higher satisfaction with short implants because of the simplicity of the surgical procedure and lesser discomfort. These results go along with the increasing popularity of simplified, patient-centered approaches in posterior maxillary rehabilitation [9].

All-Ceramic vs. Porcelain-Fused-to-Metal Crowns

Gallucci, German O et al. evaluated single-implant restorations with all-ceramic screw-retained and PFM crowns. It noted that all-ceramic restorations had superior WES due to their translucency and lifelike properties, making them suitable in highly aesthetic requirements. Conversely, PFM crowns provided slightly better strength, a difference that ceramic technology innovation reduces, indicating that all-ceramic restorations should be the first choice when anterior restorations are involved [10].

The Pink Esthetic Score (PES) and White Esthetic Score (WES) are highly validated tools for determining the aesthetic success of an implant-supported prosthesis, especially in the anterior area where aesthetics are critical. Such scoring systems have been proved to be reliable, where zirconia crowns show a better score than PFM crowns [11]. According to some studies, it is



accepted that a PES/WES threshold score of 12 is clinically acceptable and, therefore, generally accepted. On the other hand, a score of 17 indicates excellent aesthetics. Dentists become more sensitive to aesthetic losses than lay people, which creates a need for professional appraisals [12]. Provisionalization techniques, including both CAD/CAM and chairside methods, show outcomes of PES comparable enough, whereas approaches like the socket shield technique have proven their effect in preserving soft tissue aesthetics. Although PES/WES has a structured framework behind it, subjective perceptions always play a role in making the outcomes less predictable regarding universally satisfactory implant aesthetics.

Future Directions

These findings further underscore the requirement for long-term studies that establish these modalities within more diverse populations and different clinical settings. Future studies focused on patient-oriented outcomes, economics, and durability of the biologic effects will contribute to a better framework of decision making.

CONCLUSION

These studies add further integration of technology, advanced materials, and minimally invasive techniques in current implantology. Fully guided digital systems, screw-retained designs, and innovative materials like lithium disilicate come forth as pivotal tools that are essential to obtain predictable and aesthetically beautiful results in the anterior maxilla. Intervention according to a patient-specific need and specific clinical condition helps the practitioner optimize the best result with minimal emphasis on long-term stability and high patient satisfaction.

References

1. Genetti, L.; Ercoli, C.; Kotsailidi, E. A.; Feng, C.; Tsigarida, A.; Russo, L. L.; Chochlidakis, K. Clinical Evaluation of Pink Esthetic Score of Immediately Impressed Posterior Dental Implants. *J. Prosthodont.* 2022, 31 (6), 496–501.
2. Belser, U. C.; Grütter, L.; Vailati, F.; Bornstein, M. M.; Weber, H.-P.; Buser, D. Outcome Evaluation of Early Placed Maxillary Anterior Single-Tooth Implants Using Objective Esthetic Criteria: A Cross-Sectional, Retrospective Study in 45 Patients with a 2- to 4-Year Follow-up Using Pink and White Esthetic Scores. *J. Periodontol.* 2009, 80 (1), 140–151.
3. Vidigal, G. M., Jr; Groisman, M.; Clavijo, V. G.; Barros Paulinelli Santos, I. G.; Fischer, R. G. Evaluation of Pink and White Esthetic Scores for Immediately Placed and Provisionally Restored Implants in the Anterior Maxilla. *Int. J. Oral Maxillofac. Implants* 2017, 32 (3), 625–632.
4. Jones, A. R.; Martin, W. Comparing Pink and White Esthetic Scores to Layperson Perception in the Single-Tooth Implant Patient. *Int. J. Oral Maxillofac. Implants* 2014, 29 (6), 1348–1353.
5. Donker, V. J. J.; Raghoobar, G. M.; Slagter, K. W.; Hentenaar, D. F. M.; Vissink, A.; Meijer, H. J. A. Immediate Implant Placement with Immediate or Delayed Provisionalization in the Maxillary Aesthetic Zone: A 10-Year Randomized Trial. *J. Clin. Periodontol.* 2024, 51 (6), 722–732.
6. Lou, F.; Rao, P.; Zhang, M.; Luo, S.; Lu, S.; Xiao, J. Accuracy Evaluation of Partially Guided and Fully Guided Templates Applied to Implant Surgery of Anterior Teeth: A Randomized Controlled Trial. *Clin. Implant Dent. Relat. Res.* 2021, 23 (1), 117–130.
7. Amorfini, L.; Storelli, S.; Mosca, D.; Scanferla, M.; Romeo, E. Comparison of Cemented vs Screw-Retained, Customized Computer-Aided Design/computer-Assisted Manufacture Zirconia Abutments for Esthetically Located Single-Tooth Implants: A 10-Year Randomized Prospective Study. *Int. J. Prosthodont.* 2018, 31 (4), 359–366.
8. Zamora, G. P.; Molina-González, J. M.; Martínez-Marco, J. F.; Ruiz, A. J. O.; Mardas, N.; Garcia-Sanchez, R. Aesthetic Outcomes of Different Materials for Delayed, Single-Tooth Restorations for Immediately Placed Implants. A Randomized Controlled Clinical Trial. *J. Dent.* 2024, 146 (105067), 105067.
9. Nielsen, H. B.; Schou, S.; Bruun, N. H.; Starch-Jensen, T. Professional and Patient-Reported Outcomes of Two Surgical Approaches for Implant-Supported Single-Crown Restoration: 1-Year Results of a Randomized Controlled Clinical Trial. *Clin. Oral Implants Res.* 2022, 33 (2), 197–208.
10. Gallucci, G. O.; Grütter, L.; Nedir, R.; Bischof, M.; Belser, U. C. Esthetic Outcomes with Porcelain-Fused-to-Ceramic and All-Ceramic Single-Implant



Crowns: A Randomized Clinical Trial: Esthetic Outcomes with PFM and All-Ceramic Single-Implant Crowns. *Clin. Oral Implants Res.* 2011, 22 (1), 62–69.

11. Dash, S.; Srivastava, G.; Padhiary, S. K.; Samal, M.; Çakmak, G.; Rocuzzo, A.; Molinero-Mourelle, P. Validation of the Pink Esthetic Score/white Esthetic Score at Single Tooth-Supported Prosthesis in the Esthetic Zone: A Randomized Clinical Trial. *J. Esthet. Restor. Dent.* 2024, 36 (7), 976–984.
12. Srimaneekarn, N.; Arayapisit, T.; Booncharoensombat, S.; Nanayon, T.; Choterungruangkorn, N.; Kunavisarut, C.; Nakaparksin, P. Establishing a Clinically Acceptable PES/WES Threshold for Single-Tooth Implant Restorations. *Int. J. Oral Maxillofac. Implants* 2024, 39 (6), 904–910.